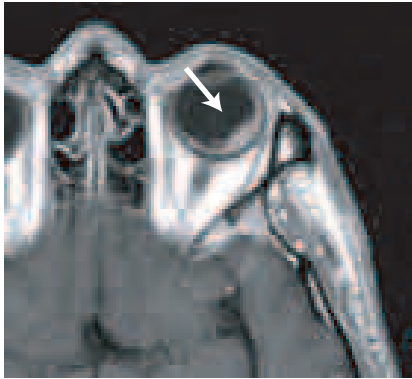


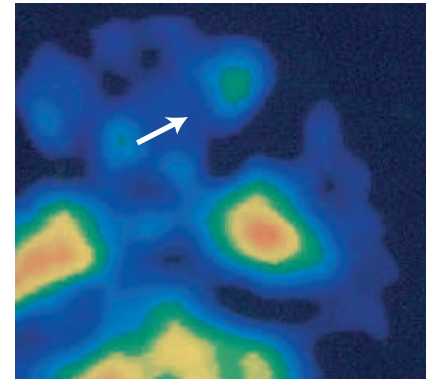
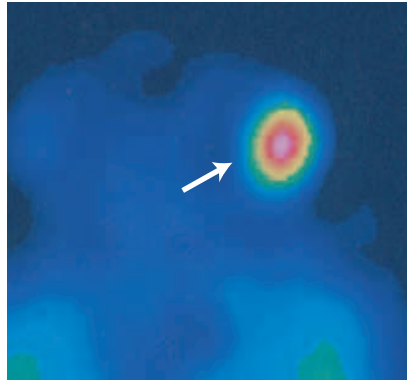
## CASE STUDY

# Choroidal Melanoma



Courtesy of H. Shiomi MD, Osaka University, Osaka, Japan

BEFORE TREATMENT



8 MONTH FOLLOW-UP

### Patient History

A 32-year-old male presented with a 5 month history of left eye discomfort. A biopsy was not performed due to the added risk of profuse hemorrhaging. Scintigraphy and MRI showed the patient had a choroidal melanoma. Surgical enucleation was recommended but the patient refused.

### CyberKnife Advantage

Proton beam irradiation and brachytherapy, while reasonable options, are not capable of real-time imaging during the course of treatment.

### Treatment

The patient was treated with the frameless CyberKnife using a motion detector developed at Osaka University, which enabled monitoring of eye movement during treatment. The patient gazes at the motion detector during treatment enabling the operator to pause the treatment in the event of any eye movement. The patient was treated with 3 fractions to 60Gy.

### Outcome & Follow-Up

Follow-up MRI showed the size of the tumor was unchanged. However, 123I scintigraphy revealed uptake by the tumor was reduced. Although there was some expected diminishment in the patient's vision, this treatment proved to be quite effective.

### CyberKnife Team



Hiroya Shiomi, M.D., D.M.Sc

Toshihiko Inoue, M.D., D.M.Sc