

## OPTIC APPARATUS MENINGIOMA

---



**Barrow Neurological Institute CyberKnife Team:**

*Radiation Oncologist:* John Kresl, M.D., Ph.D.  
*Surgeon:* Randal Porter, M.D.  
*Medical Physicist:* Ray Rodebaugh, Ph.D.  
*Radiation Therapist:* Bill Howe, R.T.(T.)

**CyberKnife Center:**

Saint Joseph Hospital  
Barrow Neurological Institute  
Phoenix, AZ

# OPTIC APPARATUS MENINGIOMA

## DEMOGRAPHICS:

**Sex:** F  
**Age:** 56  
**Histology:** Meningioma  
**Treat Date(s):** 10/18-22/2004

## CLINICAL HISTORY:

**Referred by:** Neurosurgery  
**Previous Treatment:** Resection of an optic nerve meningioma in 1983.

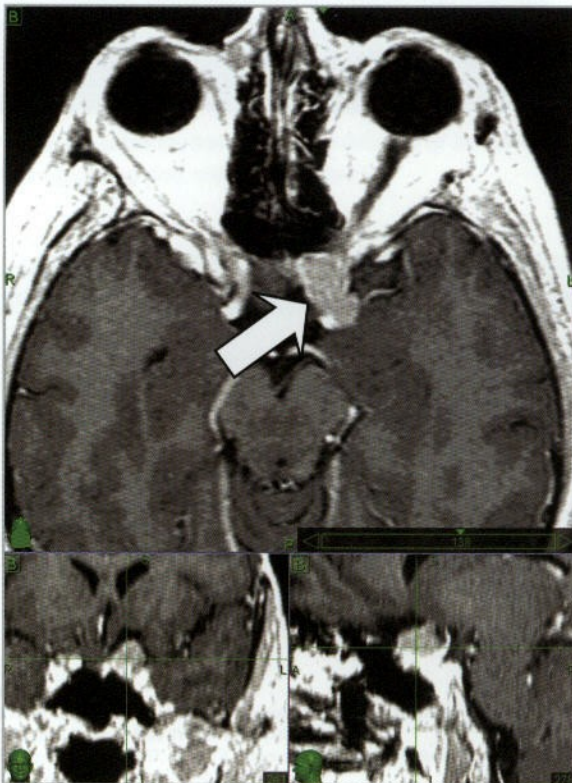
### Case History:

The patient underwent a left frontal craniotomy with a gross total resection. Ten years later she lost vision in her left eye due to tumor recurrence. In August 2004, she had a left lateral orbital wall decompression and left medial orbital wall decompression. Her vision did not improve. She was also diagnosed with Graves ophthalmopathy. Her best post-op status was restricted to shadow and light vision.

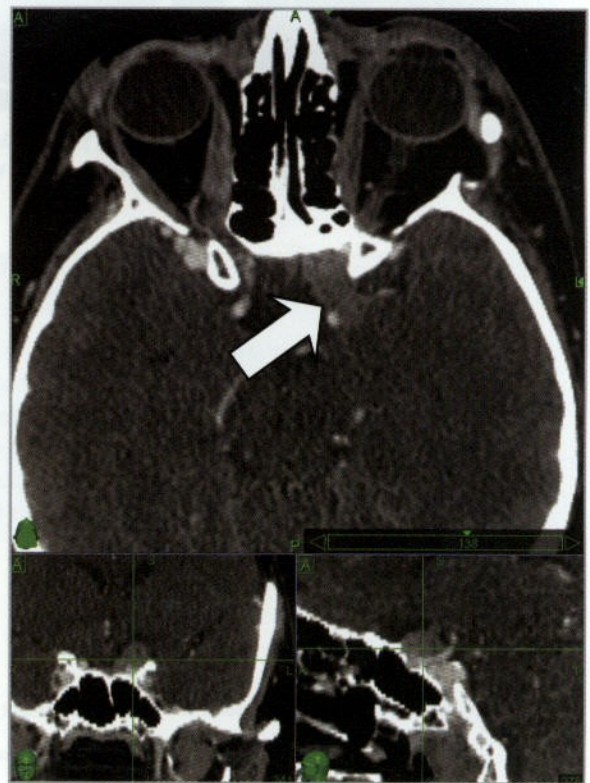
### CyberKnife Treatment Rationale:

Because of previous extent of disease, the patient excluded surgery to avoid the surgical complication risk of complete blindness. The left optic nerve would have been in great jeopardy of devascularization from a surgical approach. Surgery was unlikely to improve or restore her visual acuity. There was jeopardy of vision loss to the remaining sighted right eye with the risk of meningioma progression to extend posteriorly and involving the chiasm and other optic apparatus structures.

Treatment with CyberKnife® radiosurgery utilizing a hypofractionated treatment regimen was indicated for maximum local control and to minimize injury to the optic apparatus.<sup>1,2</sup>



Pretreatment MR data obtained on 10/8/04 used for tumor identification and image fusion.



Pretreatment CT data obtained on 10/12/04 used for treatment planning and stereotactic radiosurgical targeting on the CyberKnife System.

# OPTIC APPARATUS MENINGIOMA

## TREATMENT DETAILS:

**Tumor Volume:** 3.2 cc  
**Imaging Technique(s):** CT, MRI  
**Rx Dose & Isodose:** 25 Gy to 75%  
**Conformality Index:** 1.39  
**Tumor Coverage:** 97.7%

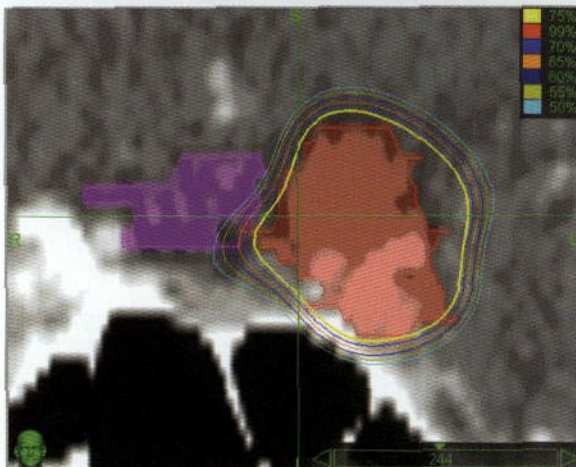
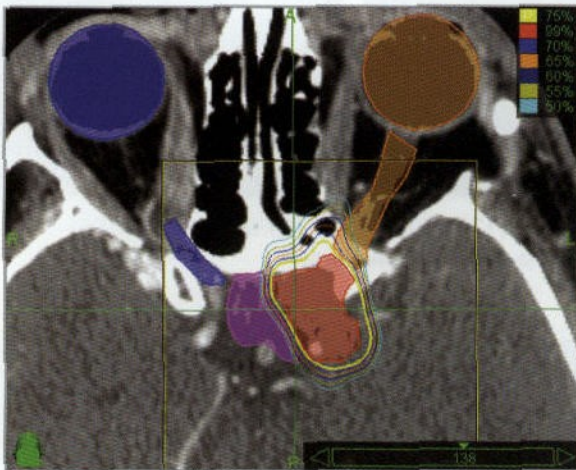
**Fractions / Treatment Time:** 5 / 40 minutes per fraction  
**Path Template:** 3 path 800 mm  
**Tracking Method:** 6D Skull Tracking  
**Collimator(s):** 7.5 mm  
**Number of Beams:** 208

## Treatment Planning Process:


The tumor target volume and surrounding critical structures were contoured to fully reconstruct a three-dimensional tumor target to include critical structure volumes. The tumor target volume measured 3.18 cc. The treatment plan was prescribed to the 75% isodose line to the margin of the target volume and was prescribed to deliver 25 Gy in five fractions of 5 Gy each. The tumor target volume was covered by 97.7% using this plan. It provided a 1.33 homogeneity index score and a 1.39 conformality index score.

## Treatment Delivery:

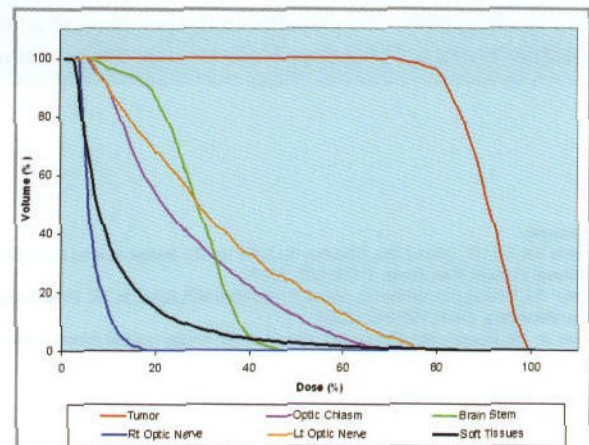
The treatment utilized 208 separately targeted 7.5 mm targeted beams from 78 different robotic positional nodes. The maximum dose to the tumor site was 33.3 Gy. The maximum dose to the critical structures are as follows: brain stem = 16.03 Gy, optical chiasm = 24.4 Gy, right optic nerve = 5.77 Gy, left optic nerve = 25.3 Gy, right eye = 1.2 Gy, left eye = 4.7 Gy. The treatment was delivered on five consecutive days. The patient reported no negative side effects.



Axial and coronal planning images with the tumor, isodose curves and critical structures. Note how the highly conformal dose distribution avoids critical optic apparatus anatomy.



AP 3D Image and CyberKnife SRS Beam Positions.



Dose Volume Histogram (DVH) for all key structures.

# OPTIC APPARATUS MENINGIOMA

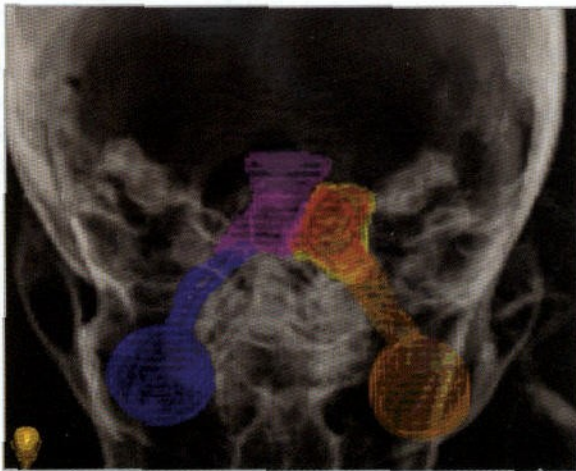
## Outcome and Follow-Up:

The patient was seen for a follow up evaluation approximately four weeks after completing CyberKnife Stereotactic Radiosurgery.

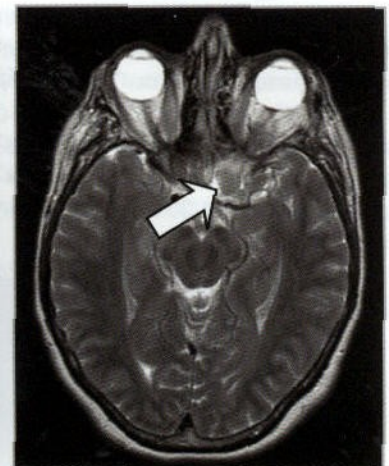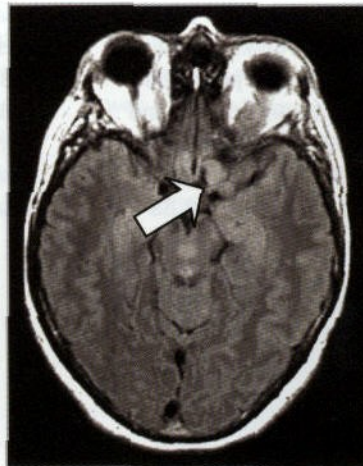- The patient reports return of sight during this period; she reports some diplopia and dysconjugate gaze.
- She is able to perceive light, color, movement and can read large text with the left eye without corrective lenses.
- The patient reports a significant subjective improvement to her left eye vision after CyberKnife Stereotactic Radiosurgery.
- A follow up MRI obtained on 12/6/04 and compared to the diagnostic MRI from 9/12/04 reveals that the mass is stable in size.

## Conclusion and CyberKnife Advantages:

- The patient's sight has significantly improved with CyberKnife treatment and remains stable.
- CyberKnife radiosurgery "may be a safe and effective alternative to either surgery or fractionated radiotherapy for selected lesions adjacent to the optic apparatus."<sup>2</sup>
- In many cases the CyberKnife System can deliver "a more uniform dose than can standard isocentric radiosurgical instruments."<sup>3</sup>



3D anterior-superior transparent rendering of treatment volume (yellow) and critical structures.



Two month follow-up (12/08/04): T1 (Flair irFSE) and T2 (FSE) weighted MRI scans show a stable mass.

## CYBERKNIFE AT BARROW NEUROLOGICAL INSTITUTE / ST. JOSEPH'S HOSPITAL ([www.thebni.com](http://www.thebni.com))

Barrow Neurological Institute (BNI) is an internationally renowned medical center that offers care for people with brain and spine diseases, disorders and injuries. Dr. Robert Spetzler, one of the world's leading neurosurgeons, is the Director of the Institute. There are 4,000 neurological procedures performed at BNI each year including up to 500 radiosurgical procedures. CyberKnife radiosurgery began at BNI in September 2003. The Center's CyberKnife population has been 71% intracranial, 21% spine and 8% whole body. The CyberKnife System is used on those patients for whom traditional radiosurgery is not possible or in situations where patients specifically request this procedure over other treatment options.

## References:

1. Mehta VK, Le QT, Chang SD, Cherney S, Adler Jr, JR: Image-guided stereotactic radiosurgery for lesions in proximity to the anterior visual pathways: A preliminary report. *Technol Cancer Res Treat*, 1:173-180, 2002.
2. Pham CJ, Chang SD, Gibbs IC, Jones P, Heilbrun MP, Adler Jr, JR: Preliminary visual field preservation after staged CyberKnife radiosurgery for periopic lesions. *Neurosurgery*, 54(4):799-812, 2004.
3. Adler Jr, JR, Murphy MJ, Chang SD, Hancock SL: Image-guided robotic radiosurgery. *Neurosurgery*, 44:1299-1307, 1999.

